



TOXIC EFFECTS OF PARTHENIUM HYSTEROPHORUS ON HISTOLOGY OF GILLS OF FRESHWATER FISH LABEO ROHITA.

Vikhar A.M¹., R.G.Jadhao²

¹Research student, Deptt. Of Zoology,

²Associate professor and Head, corresponding Author, Deptt. Of Zoology, Shri Shivaji Science College, Amravati (M.S.)

ABSTRACT:

Toxicity study was conducted on freshwater fish *Labeo rohita* to evaluate the histological effects of *Parthenium hysterophorus* on gills of *Labeo rohita* upto 96hrs. duration i.e. 24,48,72 and 96 hrs. which shown toxic effect on gills.

Keywords: *Parthenium hysterophorus*, Gills Histology, *Labeo rohita*.

INTRODUCTION

Fresh water is an important natural resource necessary for the survival of all ecosystems. The use of water by humans for activities such as irrigation and industrial applications can have adverse impacts on down-stream ecosystems. With rapid industrialization and increase in human population, the pollution of water bodies has become a universal phenomenon in the present day world (Bela and Prasad, 2008). Water quality characteristics influence histopathological appearances of poisonous effects (Bhavan and Geraldine, 2000). As the freshwater fishes in our country constitute an important part of animal protein in rural as well as in urban areas and also in the aquatic toxicology and the toxic pollutants significantly alter certain biochemical, histological and physiological procedures when they enter into the body.

Rohu is the natural inhabitant of freshwater sections of the rivers. Rohu is a bottom feeder and prefers to feed on plant matter including decaying vegetation. Rohu attains maturity towards the end of the second year in ponds. The spawning season of rohu generally coincides with the southwest

monsoon. It is diurnal and generally solitary. It is an important aqua cultured freshwater species in South Asia and very commonly eaten in Bangladesh and the Indian states of Bihar, West Bengal. The higher concentration of toxicants bring the adverse effects on aquatic organisms, at cellular level or molecular level and ultimately lead to disorder in biochemical composition which is useful in determining different toxicants and protective mechanism of the body to resist the toxic effects of the substances (Jain and Kulshreshta, 2000). The purpose of the acute-lethal toxicity is to determine lethal toxic effect of a toxicant within a short duration of usually 96 hours or 4 days on a particular tested organism. The acute-lethal toxicity test with fish species is to help in the assessment of possible risk to similar species in natural environment (USEPA, 2000). Acute-lethal toxicity test can be done in the laboratory using static, semi-static and renewable methods as the case may be. Plant extracts are referred to as botanicals and when poisonous to fish is called piscicides (Singh and Singh, 2009). The use of toxic plants for catching fish is a common practice worldwide. The gill surface is more than half of the entire body surface area. Gills are the first organs which come in contact with environmental pollutants. Absorption of toxic chemicals through gills is rapid and therefore toxic response in gills is also rapid. (Fernandes *et al.*, 2007). Therefore, lesions in gill tissues can be the start of imbalance of the physiological and metabolic processes of fish. Gills are important not only for gaseous exchange but also for osmoregulation and excretion of toxic waste products, thus any

harm in the gills leads to impairment of such vital functions revealing respiratory distress, impaired osmoregulation and retention of toxic wastes. The gills are important organs in fish to perform respiration, osmoregulation, acid base balance and nitrogenous waste excretion. Gill is one of the most important organs directly in contact with pollutants and any kind of damage to the gill tissue of fish leads to disorder in the gas exchange process and also the decrease of ion regulation efficiency via this organ (Ajani *et. al.*, 2007).

Materials & Method :

Labeo rohita fish were collected from Nal Damayanti Dam, local fish market Amravati washed with 10% solution of Potassium Permanganate to free any fungal infections. Then acclimatized to the laboratory condition for fifteen days in large aquarium. The fish size 15 to 20 cm in length and weight 150 to 200 gm. Fishes maintained in well water and its physico-chemical characteristics analyzed following the method given in APHA(2005). Fishes fed with add libitum food, oil cake and rice bran to keep them more or less in the same state of metabolic

requirement.

A group contain ten fishes were taken in both container experimental and control respectively. The dose starting from 10 ml in 10 lit. Well water. The dose increased daily by 10 ml. Their behavioral changes recorded daily and throughout the exposure period. Everyday water change to maintain the concentration of *Parthenium hysterophorus* extract and histological changes were recorded.

Result and Discussion:

For lethal concentration at control there are no lesion, no necrosis, no pigments, no malignancy, no inflammation and cellular degradation seen for the 24hrs, 48hrs, 72hrs, and 96hrs.

At 3.00ml/l lesion and inflammation on primary gill lamellae for 24hrs. While lesion, inflammation and pigments occurs on primary gill lamellae for 48hrs. and pigment, necrosis in primary gill lamellae and inflammation occurs on secondary gill lamellae for 72hrs. while for 96hrs. necrosis, pigment and inflammation occurs on primary and secondary gill lamellae .

Gill (Section) of *Labeo rohita* exposed to lethal concentration (control) of root water extract of *Parthenium hysterophorus*

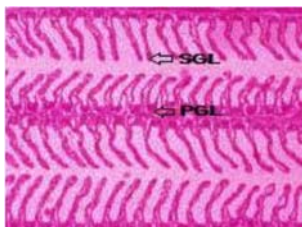


Fig.- Gill of *Labeo rohita* (Control).

PGL: Primary gill lamellae, SGL: Secondary gill lamellae. No lesion (L), inflammation (I), pigment (P), necrosis (N), malignancy (M) and cellular degeneration (C).




Fig.: Gill (Section) of *Labeo rohita* exposed to lethal concentration (3.00 ml/l) of root water extract of *Parthenium hysterophorus* showing lesion (L), inflammation (I), pigment (P) and necrosis (N).

The gills of fish exposed lethal concentration for different time exposure (24hrs. 48hrs. 72hrs. and 96hrs.) showed lesion, inflammation, pigment and necrosis of primary and secondary gill lamellae during low concentration while, increasing concentration for different time exposure showed necrosis, malignancy and cellular degeneration were seen at later time of exposure. Histological analysis is a very sensitive parameter which is crucial for determining the cellular change generated by pollutant exposure in target organs. The gills, which participate in many important functions in the fish such as respiration, osmoregulation and excretion, remain in close contact with external environment and are particularly sensitive to changes in the quality of the water, are considered the primary target of contaminants (Camargo and Martinez, 2007). In the present investigation, histological effects of extracts of *Parthenium hysterophorus* on *Labeo rohita* indicated lesion, inflammation, pigment, necrosis, malignancy and cellular degeneration on the gill after exposure. This agrees with (Fafioye *et al.*, 2008) in which there to effluent from Chemistry Department Laboratories. In the present study the histological changes in gills of fish species exposed to extract shows mucus extrusion, lamellar swelling, fused and reduced microridges. Similar observation was observed in blud gill sunfish, *Lepomis macrochirus* to different sub lethal concentrations of monocrotophos on the gills of *Anabas testudineus* by (Santhakumar *et al.*, 2001). Gill is one of the most important organs directly in contact with pollutants and any kind of damage to the gill tissue of fish leads to disorder in the gas exchange process and also the decrease of ion regulation efficiency via this organ (Ajani *et al.*, 2007).

CONCLUSION

The gills of fish exposed lethal concentration for different time exposure (24hrs. 48hrs. 72hrs. and 96hrs.) showed lesion, inflammation, pigment and necrosis of primary and secondary gill lamellae during low concentration while, increasing concentration for different time exposure showed necrosis, malignancy and cellular degeneration were seen at later time of exposure.

REFERENCES

- Adesina, B. T. (2008):** Toxicity of *Moringa oleifera* (Lam.) extract to *Oreochromis niloticus* fingerlings and juveniles. Ph.D. Thesis, University of Ibadan, Nigeria. 272pp.
- Ajani F., Olukunle O. A. and Agbede S. A., (2007):** Hormonal and hematological responses of *Clarias gariepinus* (Burchell, 1822) to nitrate toxicity. *Journal of Fisheries International* 2(1):48–53.
- Alazemi B.M.; Lewis J.W. & Andrews E.B. (1996):** Gill damage in the freshwater fish, *Gnathonemus petersii* (Family: Mormyridae) exposed to selected pollutants: an ultra structural study. *Environmental Technology*, 17, 225-238.
- APHA, (2005):** Standard method for the examination of IBERUS, water and waste water. American Public Health Association, Washington, D.C.
- Bela, Z. and R. Prasad (2008):** Impact of pollution on fresh and marine water resources. *J. Pollution Res.* 273: 461-466.
- Bhavan, P.S. and P. Geraldine, (2000):** Histopathology of the hepatopancreas and gills of the prawn *Macrobrachium malcolmsonii* exposed to endosulfan. *Aqua. Toxicol.* 50: 331-339.
- Camargo, M. M. P. and C. B. R. Martinez (2007):** Histopathology of gills, kidney and liver of a Neotropical fish caged in an urban stream. *Neotropical Ichthyology*, 5 (3): 327-336.
- Fafioye, O.O., Adeogun, A.O. and Omoniyi, I.T. (2008):** Lethal Limits and Respiration in the Cichlid Fishes, *Tilapia zillii*, *Sarotherodon galilaeus*, *S. melanotheron* and *Oreochromis niloticus* Exposed to Effluent from Chemistry Department Laboratories. *J. Appl. Sci. Environ. Manage.*, 12(1): 63-66.
- Fernandes .et. al (2007):** Histopathological changes in liver and gill epithelium of Nile tilapia, *Oreochromis niloticus* exposed to waterborne copper. *Pesq. Vet. Bras.*, 27(3), 103-109.

Santhakumar, M., Balaji, M. and Ramudu, K. (2001): Gill lesions in the perch *Anabus testudineus*, exposed to monocrotrophos. *J. Environ. Biol.*, **22**: 87-90.

Singh, S. K., R.P. Yadav and A. Singh, (2009): Molluscicides from some common medicinal plants of Eastern Uttar Pradesh, India. *J. App. Toxicol.*, 29: In press.

USEPA (2000): Methods for measuring the acute toxicity of effluents to freshwater and marine organisms. 4th ed. Environmental Monitoring and support Laboratory, U.S. Environmental Protection Agency, Cincinnati, Ohio. EPA 600/4-85/013.